

Prevalence of eye colobomas in wild birds: insights from a large-scale citizen science study

Authors: Mikula, Peter, Šálek, Martin, Adojaan, Kristjan, Alonso, Agustin D.L., Baltag, Emanuel, et al.

Source: Journal of Vertebrate Biology, 74(24117)

Published By: Institute of Vertebrate Biology, Czech Academy of Sciences

URL: <https://doi.org/10.25225/jvb.24117>
















The BioOne Digital Library (<https://bioone.org/>) provides worldwide distribution for more than 580 journals and eBooks from BioOne's community of over 150 nonprofit societies, research institutions, and university presses in the biological, ecological, and environmental sciences. The BioOne Digital Library encompasses the flagship aggregation BioOne Complete (<https://bioone.org/subscribe>), the BioOne Complete Archive (<https://bioone.org/archive>), and the BioOne eBooks program offerings ESA eBook Collection (<https://bioone.org/esa-ebooks>) and CSIRO Publishing BioSelect Collection (<https://bioone.org/csiro-ebooks>).

Your use of this PDF, the BioOne Digital Library, and all posted and associated content indicates your acceptance of BioOne's Terms of Use, available at www.bioone.org/terms-of-use.

Usage of BioOne Digital Library content is strictly limited to personal, educational, and non-commercial use. Commercial inquiries or rights and permissions requests should be directed to the individual publisher as copyright holder.

BioOne is an innovative nonprofit that sees sustainable scholarly publishing as an inherently collaborative enterprise connecting authors, nonprofit publishers, academic institutions, research libraries, and research funders in the common goal of maximizing access to critical research.

Prevalence of eye colobomas in wild birds: insights from a large-scale citizen science study

Peter MIKULA^{1,2,3*} , Martin ŠÁLEK^{3,4} , Kristjan ADOJAAN⁵ , Agustin D.L. ALONSO⁶, Emanuel BALTAG⁷ , Damla BETON⁸ , Ingrid BOBEKOVÁ⁹, Rodrigo A.M. CATALÁN¹⁰, Kiraz ERCIYAS-YAVUZ¹¹ , Alessandro FRANZOI¹² , Erpur S. HANSEN¹³ , Luboš KORYTÁR¹⁴ , Pavel LINHART¹⁵ , Verónica MÉNDEZ⁹ , Ákos MONOKI¹⁶, Anna ONDREJKOVÁ¹⁴ , Alexandru-Mihai PINTILIOAIE¹⁷ , Lorenzo SERRA¹⁸ , Robin T.E. SNAPE⁸, Nizamettin YAVUZ¹¹  and Piotr TRYJANOWSKI^{1,2,19} 

¹ TUM School of Life Sciences, Ecoclimatology, Technical University of Munich, Freising, Germany; e-mail: petomikula158@gmail.com

² Institute for Advanced Study, Technical University of Munich, Garching, Germany

³ Faculty of Environmental Sciences, Czech University of Life Sciences Prague, Praha, Czech Republic

⁴ Institute of Vertebrate Biology, Czech Academy of Sciences, Brno, Czech Republic

⁵ Vaibla Bird Observatory, Vaibla, Viljandimaa, Estonia

⁶ Department of Ornithology, Aranzadi Sciences Society, Donostia, Spain

⁷ Marine Biological Station 'Prof. Dr. Ioan Borcea', Agigea, 'Alexandru Ioan Cuza' University of Iași, Romania

⁸ The Society for the Protection of Birds and Nature (KUŠKOR), Nicosia, Cyprus

⁹ South Iceland Research Centre, University of Iceland, Laugarvatn, Iceland

¹⁰ Nature Specialist/Offshore Department – BioConsult SH GmbH & Co. KG, Husum, Germany

¹¹ Ornithological Research Center, Ondokuz Mayıs University, Atakum, Samsun, Turkey

¹² Ufficio Ricerca e Collezioni museali, Muse – Museo delle Scienze, Trento, Italy

¹³ South Iceland Nature Research Centre, Vestmannaeyjar, Iceland

¹⁴ Department of Epizootiology, Parasitology and Protection of One Health, University of Veterinary Medicine and Pharmacy in Košice, Košice, Slovakia

¹⁵ Department of Zoology, Faculty of Science, University of South Bohemia, České Budějovice, Czech Republic

¹⁶ Ranger Service, Hortobágy National Park Directorate, Debrecen, Hungary

¹⁷ Laboratory of Interdisciplinary Research on the Marine Environment and Marine Terrestrial Atmosphere, 'Alexandru Ioan Cuza' University of Iași, Marine Biological Station 'Prof. Dr. Ioan Borcea', Agigea, Constanța, Romania

¹⁸ Area Avifauna Migratrice, Istituto Superiore per la Protezione e la Ricerca Ambientale (ISPRA), Ozzano Emilia, Italy

¹⁹ Institute of Zoology, Poznań University of Life Sciences, Poznań, Poland

► Received 2 November 2024; Accepted 26 January 2025; Published online 24 February 2025

Abstract. Colobomas are inherited defects affecting the membranes of the eye, leading to irregularities in the shape of the iris and pupil. While the causes and occurrence of colobomas have been studied extensively in humans and captive or domesticated animals, their prevalence in wild birds (which may represent interesting

* Corresponding Author



model organisms) remains largely unexplored. In this study, we developed a citizen science project which conducted fieldwork to assess the presence of eye colobomas in relation to species and sex, examining 58,651 individuals from 179 wild bird species across Europe. We identified 17 cases of colobomas in nine bird species during the screening. Although the overall prevalence was low (2.90 cases per 10,000 individuals), a notably higher prevalence was observed in several owl species (Strigidae), with rates exceeding 100 cases per 10,000 individuals. Among six sexed Eurasian scops owls *Otus scops* with colobomas, all were females, while in little owls *Athene noctua*, both positive cases were males. Our findings suggest that certain wild bird species could serve as valuable subjects for studying colobomas, though further research involving more extensive sampling and visual inspection, along with cytological and genetic analyses, is necessary to estimate coloboma prevalence across birds accurately.

Key word: birds, community science, Europe, eye defects

Introduction

Colobomas are congenital and sex-linked malformations of the eye's membranes, causing aberrations in the shape of the iris, pupil, lens, retina, or another part of the eye (Abbott et al. 1970, Gregory-Evans et al. 2004, Chan et al. 2021). Colobomas typically arise from abnormal eye development during prenatal development and occur when the optic fissure fails to close (Gregory-Evans et al. 2004, Chan et al. 2021). Failure of optic fissure closure is linked to numerous internal factors, including genetic and chromosomal aberrations as well as external environmental stressors, including toxin exposition, vitamin deficiency and parasitic and viral infections (Gregory-Evans et al. 2004, Verma & FitzPatrick 2007); the effect of factors causing eye coloboma have been explored mainly in humans and captive/domesticated animals (Wilcox 1958, Gregory-Evans et al. 2004, Chan et al. 2021). Coloboma is often associated with microphthalmia, an eye condition where one or both eyes are abnormally small (Gregory-Evans et al. 2004, Verma & FitzPatrick 2007, Aldahmesh et al. 2012). Colobomas may occur in one or both eyes and, depending on their position and size, can be associated with significant visual impairment or even blindness of the affected individual (Chan et al. 2021).

Colobomas are relatively rare malformations in humans, occurring in only one or two per 10,000 newborn babies (Stoll et al. 1997, Morrison et al. 2002). In captive animals such as birds, this defect may be more prevalent and possibly sex-specific (Wilcox 1958, Cardona & Plumer 2004). In contrast, this malformation is rarely described in wild-living birds; Lord (1956) reported two adult individuals of rough-legged hawk *Buteo lagopus* and red-tailed hawk *B. jamaicensis* exhibiting unilateral colobomas which involved a lack of development or atrophy of approximately three-fourths of the iris, lens, retina,

and choroid. It seems that heterogametic sex (i.e. ZW females in birds and XY males in mammals) is more severely affected by colobomas. For example, colobomas were present in 26% of females but only 9% of males in a single flock of rosecomb bantam chickens (Cardona & Plumer 2004). Moreover, the presence of coloboma may cause more serious craniofacial malformations in the skull, beak, and throat in more sensitive sex (Abbott et al. 1970, Robb et al. 2013). Wild birds, as a diverse vertebrate clade, may potentially represent interesting model organisms for the study of eye malformations. In both wild and captive birds, the occurrence of coloboma is rare; hence, large sample sizes are needed to detect it. Accordingly, collaborative citizen science (in broad interpretation, this includes not only general public and amateur experts but also scientists trained in other fields; Shirk et al. 2012) can be a valuable tool to provide large data sets across broad geographic areas, particularly in the case of relatively rare natural phenomena (Sullivan et al. 2014, Mikula et al. 2016, Pesendorfer et al. 2018).

In this study, through an established regional collaborative research platform for monitoring wild birds, we developed a citizen project utilising trained volunteers across Europe to conduct cross-national and cross-species field surveys to document the occurrence of coloboma among wild bird species. We used only data from systematic field surveys, which simultaneously documented both positive and negative cases, enabling us to estimate the prevalence of this malformation in sampled species.

Material and Methods

Data collection procedure

In February 2023, we emailed a brief description of our project, data requirements and methods to 48 EURING member ringing schemes. In brief, we asked potential

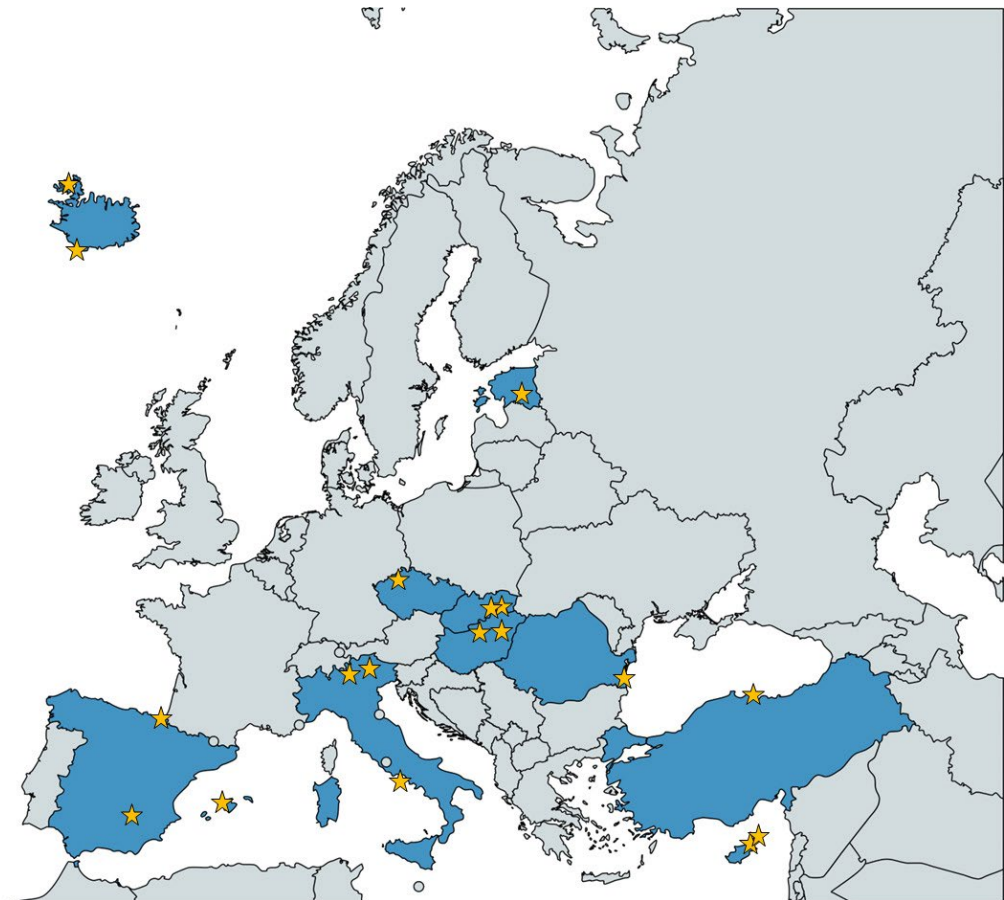


Fig. 1. Distribution of our sampling localities in Europe. Yellow stars depict sampling points, and blue indicates sampled countries. For details on the exact position of localities, see the Material and Methods section. Note that not all points are visible – in two cases (Cyprus and Slovakia), we merged closely positioned points into a single star to improve map clearness.

collaborators to provide any previously collected data and/or to collect new data for the project during the period February 2023 and September 2024. In the latter case, we asked to check only mist-netted birds and note down both positive and negative cases of sampled birds, accompanied by geographic sampling area species names and coordinates, date and any additional details of sampled birds, such as sex. Of the 48 contacted centres, 13 forwarded our request to their members. We also asked two collaborators with whom our research group has previous personal connections to contribute their data. Our sampling areas cover ringing points in Cyprus (Dipkarpaz 35°36'21" N, 34°22'55" E; Karpaz 35°39'34" N, 34°33'14" E; Golden Beach marsh 35°38'35" N, 34°32'14" E), Czechia (Northern Bohemia 50°23' N, 13°40' E; for more details see Šálek et al. 2016), Estonia (Vaibla 58°24'15" N, 26°04'30" E), Hungary (Budapest 47°31' N, 19°05' E; eastern Hungary 47°33' N, 20°54' E; Šálek et al. 2016), Iceland (Westfjords 66°03' N, 22°59' W; Westman Islands 63°26' N, 20°18' W), Italy (Bocca di Caset 45°51'34" N, 10°41'25" E; Passo del Brocon 46°06'08" N, 11°41'50" E; <https://progettoalpi.muse.it/>; Ventotene Island 40°47' N, 13°25' E),

Romania (Agigea 44°05'11" N, 28°38'28" E), Spain (Mallorca 39°35'18" N, 2°19'46" E; Albacete 38°46'48" N, 2°22'40" W; Hondarribia 43°22'21" N, 1°48'36" W), Slovakia (Košice – Horný Bankov 48°44'44" N, 21°12'55" E; Rozhanovce 48°46'21" N, 21°22'18" E; Drienovec Bird Ringing Station 48°36'59" N, 20°54'55" E) and Turkey (Cerneke Bird Ringing Station 41°38'36" N, 36°05'02" E) (Fig. 1 and Table S1). Some of the data used in this study ($n = 3,865$ individuals and six species) were collected prior to the launch of the project (1997-2022). In such cases, we ensured that the data collection adhered to the same methodology as the data gathered specifically for this project.

The eyes of sampled birds were inspected visually for any anomalies. As a positive presence of coloboma, we considered cases where the iris and pupil showed an aberrant shape, typically that one or both protruded to the sclera. However, we acknowledge that visual inspection may be less sensible towards positive cases in bird species with dark iris and sclera, potentially underestimating colobomas in these species. Moreover, research on human eyes indicates that a significant proportion of colobomas affect only




Fig. 2. Examples of (A-D) non-coloboma and presumable coloboma (E-H) eye defects. (A) Pupil defect in the left eye of the little owl *Athene noctua* is presumably affected by mechanical or other non-developmental damage (photo Martin Šálek). (B-D) Examples of three species with common eye flecks which are not related to coloboma, such as black woodpecker *Dryocopus martius* (photo Katalin Odett Lukács), Eurasian oystercatcher *Haematopus ostralegus* (photo Ingrid Bobeková) and common wood pigeon *Columba palumbus* (photo Katalin Odett Lukács), respectively. (E-G) Presumable colobomas in little owl (photo Martin Šálek), Eurasian scops owl *Otus scops* (photo Balázs Juszti), red-backed shrike *Lanius collurio* and European robin *Erithacus rubecula* (both photos Emanuel Baltag). Miniatures in the lower right corner of the picture zoom in the eye in less visible cases.

the posterior eye segment, which cannot be detected through external examination (Nakamura et al. 2011). If this is also the case in birds, our visual sampling method may further reduce the detection rates of colobomas in our sample of wild birds; however, we are not aware of a comprehensive study on this issue across birds. We tried to detect and exclude cases when the iris/pupil structure was affected by non-congenital defects such as mechanical injury or congenital eye defects that can resemble coloboma but are caused by different mechanisms and developmental issues. A coloboma of the iris/pupil can cause an irregular-shaped iris/pupil, which might be mistaken for anisocoria (iris/pupil size difference between the two eyes) if only one eye is affected; hence, we excluded cases when iris/pupil size differed between the two eyes but without significant defect in iris pupil shape.

We also checked for cases of aniridia (i.e. a partial or complete absence of the iris), Peters' anomaly (affects primarily cornea, which is clouded, and there is an abnormal attachment between the cornea and the iris or lens) and sclerocornea (cornea becomes opaque and blends with the sclera) but we did not detect them. We excluded from our analysis species that exhibit a high prevalence of eye structures resembling colobomas but are, in fact, dark eye flecks that have different origins and development than colobomas (see also Guzzetti et al. 2008). These include shorebirds (Charadriiformes), such as the Eurasian oystercatcher (*Haematopus ostralegus*), as well as the black woodpecker (*Dryocopus martius*) and the common wood pigeon (*Columba palumbus*), including these species could have significantly but falsely overestimated the frequency of colobomas.

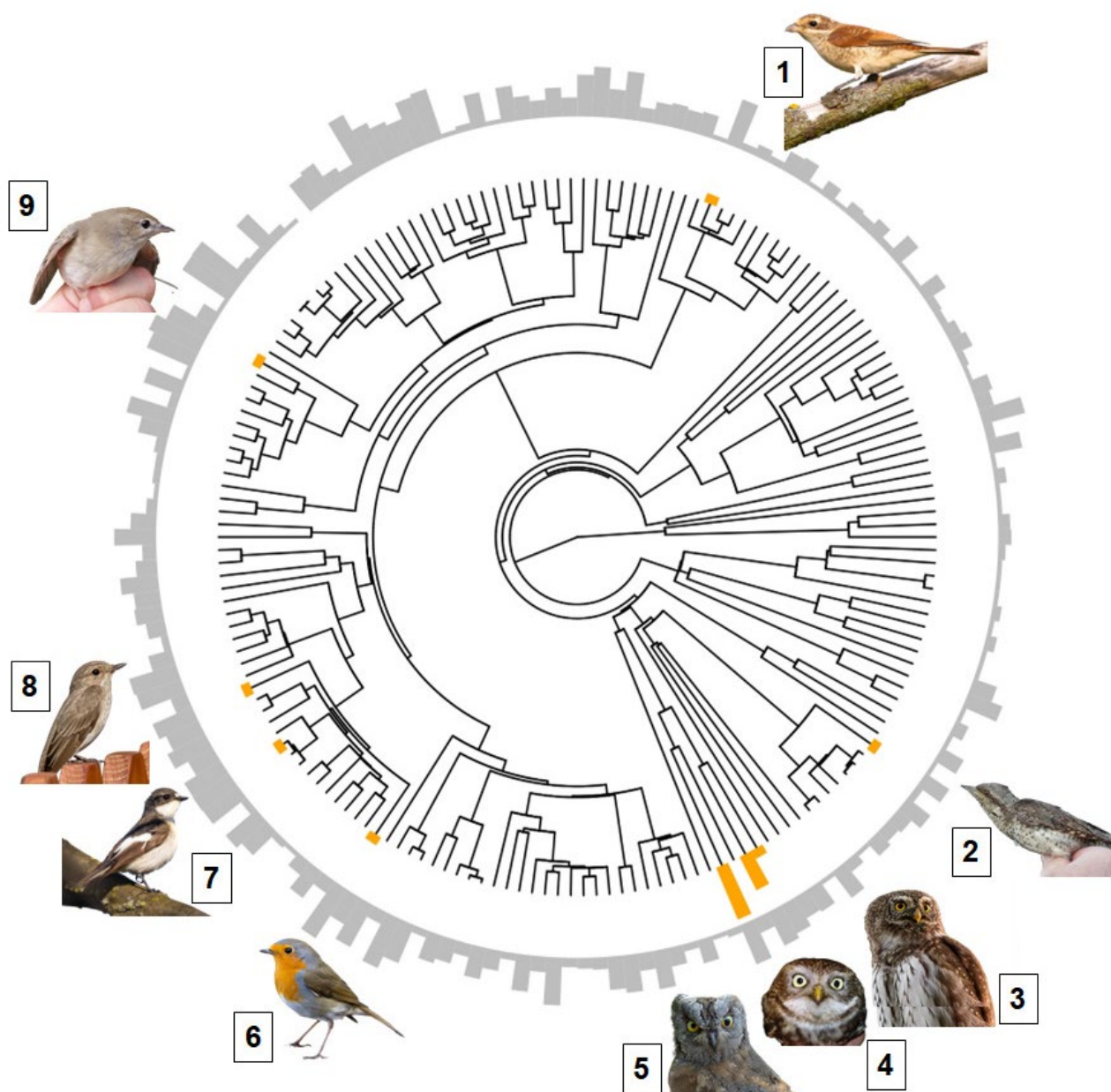


Fig. 3. Distribution of coloboma across the phylogenetic tree of birds covering 179 species sampled in this study. Orange bars show the presence of coloboma across species; grey bars show sampling effort; the height of the bars is proportional to the number of observations (note that values with grey bars were log-transformed due to unequal sampling effort, range = 1-9,776 observations per species). Pictures show species with a positive discovery of coloboma (clockwise): (1) red-backed shrike *Lanius collurio*, (2) Eurasian wryneck *Jynx torquilla*, (3) Eurasian pygmy owl *Glaucidium passerinum*, (4) little owl *Athene noctua*, (5) Eurasian scops owl *Otus scops*, (6) European robin *Erithacus rubecula*, (7) European pied flycatcher *Ficedula hypoleuca*, (8) spotted flycatcher *Muscicapa striata*, (9) garden warbler *Sylvia borin*. Photos were taken by Jan Grünwald (photos: 1, 3, 6-8), Peter Mikula (2), Martin Šálek (4), Balázs Jusztin (5), and Ľuboš Korytár (9).

Finally, we calculated the prevalence of coloboma in wild birds by dividing the number of positive cases by the total number of sampled birds. We also calculated the binomial proportion confidence interval for each species using the *binom.confint* function in the *binom* v. 1.1-1.1 package (Dorai-Raj 2014). We used the 'exact' method of confidence interval estimation, which is particularly suitable for small sample sizes.

Results

Data were provided from ten countries distributed between 33° in the south, 67° in the north, 36° in the east and 23° in the west (Fig. 1 and Table S1). We identified 17 cases of colobomas (2.9 cases per 10,000 sampled birds; 95% CI (1.7-4.6)) in nine wild bird species during our screening of 58,651 individuals



from 179 species (Figs. 2 and 3). Among species with at least one positive coloboma finding, the prevalence per 10,000 individuals was as follows (in decreasing order): 160 (43.8-404.6) in little owl *Athene noctua* (four cases in 250 individuals), 149 (3.8-803.8) in Eurasian wryneck *Jynx torquilla* (one in 67), 111 (40.9-240.3) in Eurasian scops owl *Otus scops* (six in 540), 83 (2.1-455.6) in Eurasian pygmy owl *Glaucidium passerinum* (one in 120), 17 (0.4-95.0 and 0.4-91.7, respectively) in spotted flycatcher *Muscicapa striata* (one in 584) and European pied flycatcher *Ficedula hypoleuca* (one in 605), 14 (0.3-76.9) in garden warbler *Sylvia borin* (one in 722), nine (0.2-51.4) in red-backed shrike *Lanius collurio* (one in 1,081), and two (0.1-10.4) in European robin *Erithacus rubecula* (one in 5,379). Notably, no colobomas were detected in several well-sampled species, including barn swallow *Hirundo rustica* ($n = 9,776$), common chiffchaff *Phylloscopus collybita* ($n = 4,412$), willow warbler *P. trochilus* ($n = 3,993$), and other bird species (Table S2). In cases where we had information on the sex of coloboma-positive individuals, all six coloboma-positive Eurasian scops owls were females (six individuals sexed in total; all females), while the two cases in little owls were males (173 individuals sexed, 29 females and 144 males); owls were caught and sexed in the field based on a head shape, wing length, body mass, brood patch, and later also using genetics (see also van Nieuwenhuyse et al. 2008, Valterová R. et al., unpublished data).

Discussion

This study is the first of its kind in Europe and globally to document the prevalence of coloboma in wild-living bird species, offering new insights into the occurrence of this condition in avian populations. It is also the largest study in terms of geographical scope, encompassing a wide range of habitats across Europe, samples including approximately 60,000 individual wild-living birds and species diversity covering 179 bird species. It represents a pioneering application of citizen science in the study of coloboma, utilising contributions from bird ringers to enhance data collection and broaden the study's reach. We documented 17 cases of coloboma occurrence in nine wild-living species of European birds. The general prevalence of coloboma among birds was low, occurring in approximately three in 10,000 sampled birds. This rarity is similar to coloboma prevalence in humans (Stoll et al. 1997, Nakamura et al. 2011, George et al. 2020). We detected the highest prevalence of coloboma in some species of owls (Strigidae, where in two species, > 1% individuals were coloboma positive) and woodpeckers (Picidae).

Pourlis (2011) reviewed ocular malformations of birds and stated that such deformities are rarely reported in wild birds, with microphthalmia being the most frequently reported malformation and mentioning only two cases of coloboma originally reported by Lord (1956). Similarly, Kinney et al. (2017) reported only a single case of iris coloboma among 21 zoo-housed American white pelicans *Pelecanus erythrorhynchos*. Compared to other species surveyed, we detected a disproportionate occurrence of coloboma in little owls. The little owl population in Europe has declined significantly since the mid of 20th century, which resulted in the substantial contraction of its distribution range and local extinctions in Central Europe (Šálek & Schropfer 2008, van Nieuwenhuyse et al. 2008, Chrenková et al. 2017). Individuals living in small and isolated populations may be more prone to inbreeding (Pellegrino et al. 2015), potentially resulting in increased congenital diseases such as eye coloboma. In particular, a significant level of inbreeding was detected only in the study area in the Czech Republic, while it was not detected in the Hungarian population (Valterová R. et al., unpublished data), where the species still achieves a high population density (Šálek et al. 2013, 2025). However, since coloboma in little owls was detected in both populations (two cases in Hungary and one in Czechia), this topic warrants further research.

The absence of coloboma detection in most species is most likely related to relatively low sampling in most species (median = 14 observations for species; see also Fig. 3). When taking all species together, coloboma prevalence was generally low. This rarity is in accordance with previous studies showing a low occurrence of coloboma among wild animals. For example, Schmidt & Toft (1981) described an overview of ophthalmic malformations in animals from zoological collections diagnosed via biopsy or necropsy, detecting 24 and 12 such cases in birds and other vertebrates (mammals, non-avian reptiles and fish), respectively, but without a single case of coloboma. Schmidt (1971) necropsied 223 non-human primates and found four cases of eye coloboma in olive baboon *Papio anubis* (two cases), rhesus macaque *Macaca mulatta*, and chimpanzee *Pan troglodytes*. However, we found a high prevalence of coloboma in some owls and woodpeckers. This finding may suggest that the prevalence of coloboma is genuinely high in these species, making these species potentially interesting model species for further study of this phenomenon, as well as its causes and impacts. Reliable baseline estimates of coloboma prevalence among most wild-living birds



would require 1) a more intense sampling effort and 2) visual inspection supported by cytologic and genetic evaluation. For example, the two owl species with the highest rates of coloboma are both nocturnal predators, often using woodland or urban habitats. These species may be particularly prone to injury due to collisions while hunting at night (Seruca et al. 2012, Šálek et al. 2019, 2023). Therefore, genetic techniques could help confirm specific eye conditions according to the field evidence observed. Inspection for coloboma could be integrated into long-term monitoring of national ringing schemes to allow long-term monitoring and is recommended at least for owls and woodpeckers.

Most individuals with coloboma in the eye were females. This finding agrees with a previous study on chickens, showing that coloboma is sex-specific (Abbott et al. 1970, Cardona & Plumer 2004). However, our results on sex-links in coloboma must be taken with caution because of very low sampling.

Several wild bird species, such as some shorebirds (Charadriiformes) and pigeons (Columbiformes), have regularly distinct and dark eye 'flecks', which might be mistaken for coloboma during visual inspection. Interestingly, these eye flecks seem to be sex-linked, as shown in a study on sex-determination using eye flecks in black oystercatchers *Haematopus bachmani* (Guzzetti et al. 2008), species closely related to Eurasian oystercatcher *H. ostralegus* included in this study. Authors were able to correctly sex oystercatcher individuals in 94% of cases based solely on the size of eye flecks, with full eye flecks (which had a coloboma-like appearance, see Fig. 2C here or Fig. 2 in Guzzetti et al. 2008) being much more prevalent in females than in males (Guzzetti et al. 2008).

Citizen science projects such as the current study allow data to be collected on large scales with large sample sizes. However, this data availability may result in reduced data quality due to larger associated observer error, where the field teams are less experienced than the research leads. To optimise future work, the integration of guidance materials/training for regional and national ringing schemes on identifying and reporting eye defects is recommended.

Acknowledgements

We have no known conflict of interest to disclose. We are grateful to Balázs Jusztin, Progetto Alpi MUSE/ISPRA

(Paolo Pedrini, Francesca Rossi); Progetto Piccole Isole ISPRA (Andrea Ferri, Sara Riello), Katalin Odett Lukács (Hungarian Bird Ringing Centre, BirdLife Hungary), Zsolt Karcza (Hungarian Bird Ringing Centre, BirdLife Hungary), Ebelin Castaño Montaña (Aranzadi Sciences Society), William Edmond, Andy Coates, Shona Quinn, Shirley Millar, Les Hatton, Martin Moss and Tom Dougall from Lothian, Tay and Clyde Ringing Groups (Scotland), Vanesa Duceac, Vlad Amarghioalei, Ana Jurjescu, Beatrice Filote, Laura Topalã, Jakub Mráz, Jan Korbel, Miroslav Bažant, Zuzana Holubová, Malavika Madhavan, Sangeeth Sailas, Cernek Bird Ringing Station and Agigea Bird Observatory ringers for help with field data collection. P. Mikula is thankful to Anna Milosavljevičová for her support during the project.

Funding: P. Mikula was supported by the Faculty of Environmental Sciences CZU Prague within the framework of the Research Excellence in Environmental Sciences (REES 003). P. Tryjanowski and P. Mikula were supported by IAS TUM – Hans Fisher Senior Fellowship (to P. Tryjanowski). Research in Slovakia was partially supported by the project 'Vector-borne pathogens in flying vertebrate populations' (NAWA, Polish Ministry for Science and Education, BPN/BSK/2023/1/00068) and APVV SK-PL-23. The fieldwork in Slovakia was also financially supported by the projects VEGA 1/0316/23 and KEGA No. 005UVLF-4/2022 granted by the Ministry of Education, Research, Development and Youth of the Slovak Republic and the Slovak Academy of Sciences. P. Linhart and M. Šálek were funded by the Czech Science Foundation (21-04023K). M. Šálek was also supported by the Czech Academy of Sciences in the framework of the program Strategy AV 21 and the research aim of the Czech Academy of Sciences (RVO 68081766). A.-M. Pintilioaie was supported by the Romanian government through the Operational Program Competitiveness 2014-2020, Axis 1, under POC/448/1/1 Research infrastructure projects for public R&D institutions/sections F 2018, through the Research Center with Integrated Techniques for Atmospheric Aerosol Investigation in Romania (RECENT AIR) project, under grant agreement MySMIS no. 127324. Research in Turkey was supported by the Scientific Research Projects Unit of Ondokuz Mayıs University (no. PYO.ORN.1915-A.23.001).

Ethics: The birds were captured and handled by licenced ornithologists; in Slovakia, under exemption No. 3320/2019-6.3 from Act. No. 543/2002 of the code on nature and landscape protection, granted by the Ministry of Environment of the Slovak Republic (ringing licence SR 5040; E. Korytár); in Hungary, all activities were conducted under the Hungarian national license PE-KTF/97-13/2017, and in compliance with personal



certifications TMF-3/2008, TMF-14/2010, TMF-320/2017, TMF-556/2007, TMF-24/2009 and TMF-514/2004 as well ringing licence numbers 623 and 643 issued by the Ministry of Agriculture and MME Birdlife Hungary (Á. Monoki, K.O. Lukács and B. Jusztin); in Italy, all activities have been carried out in compliance of art. 4.1, 4.2 and 7 of national Law 157/92 and under ringing licenses 0601 and 2624 issued by the Italian Institute for Environmental Protection and Research (Istituto Superiore per la Protezione e la Ricerca Ambientale; ISPRA) and under project Progetto Alpi permitted by ISPRA and the Autonomous Province of Trento (Ufficio Foreste e Fauna) (L. Serra and A. Franzoi); in Turkey, bird handling was performed with the permission of the Ministry of Agriculture and Forestry, General Directorate of Nature Conservation and National Parks, according to the protocol number 21264211-288.04-10658562 and under the Ethical Principles in Animal Research approved by the Ondokuz Mayıs University Animal Ethical Committee with the protocol number: 604.01.04-2300045202 and the 2023/17 ethical number (K. Erciyas-Yavuz and N. Yavuz); in Czechia, work was performed under ringing licence 984 issued by the Bird Ringing

Centre, National Museum (M. Šálek); in Cyprus, C/6395 and C/6839 issued by the British Trust for Ornithology (R.T.E. Snape and D. Beton); in Spain, A0314 issued by the Aranzadi Bird Ringing Office (Oficina de Anillamiento de Aranzadi) (A.D.L. Alonso); in Iceland, 262, 445 and 447 issued by the Icelandic Institute of Natural History (Náttúrufræðistofnun Íslands) (E.S. Hansen, V. Méndez and I. Bobeková); in Romania, G82724 and G93124 issued by the Romanian Ministry of Environment Water and Forests (A.-M. Pintilioaie and E. Baltag).

Author Contributions

P. Mikula established the original idea, did formal analyses and visualisations, and wrote the first version of the manuscript. P. Tryjanowski supervised the project. M. Šálek, K. Adojaan, A.D.L. Alonso, E. Baltag, D. Beton, I. Bobeková, R.A.M. Catalán, A. Franzoi, K. Erciyas-Yavuz, E.S. Hansen, L. Korytár, P. Linhart, V. Méndez, Á. Monoki, A.-M. Pintilioaie, L. Serra, R.T.E. Snape and N. Yavuz collected field data. All authors read and approved the final manuscript.



Literature

- Abbott U.K., Craig R.M. & Bennett E.B. 1970: Sex-linked coloboma in the chicken. *J. Hered.* 61: 95–102.
- Aldahmesh M.A., Mohammed J.Y., Al-Hazzaa S. & Alkuraya F.S. 2012: Homozygous null mutation in ODZ3 causes microphthalmia in humans. *Genet. Med.* 14: 900–904.
- Cardona C.J. & Plumer K. 2004: Colobomas of the iris in a flock of rosecomb bantam chickens. *Avian Dis.* 48: 686–690.
- Chan B.H.C., Moosajee M. & Rainger J. 2021: Closing the gap: mechanisms of epithelial fusion during optic fissure closure. *Front. Cell Dev. Biol.* 8: 1713.
- Chrenková M., Dobrý M. & Šálek M. 2017: Further evidence of large-scale population decline and range contraction of the little owl *Athene noctua* in Central Europe. *Folia Zool.* 66: 106–116.
- Dorai-Raj S. 2014: binom: binomial confidence intervals for several parameterisations. R package version 1.1-1. <https://CRAN.R-project.org/package=binom>
- George A., Cogliati T. & Brooks B.P. 2020: Genetics of syndromic ocular coloboma: CHARGE and COACH syndromes. *Exp. Eye Res.* 193: 107940.
- Gregory-Evans C.Y., Williams M.J., Halford S. & Gregory-Evans K. 2004: Ocular coloboma: a reassessment in the age of molecular neuroscience. *J. Med. Genet.* 41: 881–891.
- Guzzetti B.M., Talbot S.L., Tessler D.F. et al. 2008: Secrets in the eyes of black oystercatchers: a new sexing technique. *J. Field Ornithol.* 79: 215–223.
- Kinney M.E., Ericsson A.C., Franklin C.L. et al. 2017: Ocular findings and select ophthalmic diagnostic tests in captive american white pelicans (*Pelecanus erythrorhynchos*). *J. Zoo Wildl. Med.* 48: 675–682.
- Lord R.D. 1956: An anomalous condition in the eye of some hawks. *Auk* 73: 457.
- Mikula P., Morelli F., Lučan R.K. et al. 2016: Bats as prey of diurnal birds: a global perspective. *Mammal Rev.* 46: 160–174.
- Morrison D., FitzPatrick D., Hanson I. et al. 2002: National study of microphthalmia, anophthalmia, and coloboma (MAC) in Scotland: investigation of genetic aetiology. *J. Med. Genet.* 39: 16–22.
- Nakamura K.M., Diehl N.N. & Mohny B.G. 2011: Incidence, ocular findings, and systemic associations of ocular coloboma: a population-based study. *Arch. Ophthalmol.* 129: 69–74.
- Pellegrino I., Negri A., Boano G. et al. 2015: Evidence for strong genetic structure in European populations of the little owl *Athene noctua*. *J. Avian Biol.* 46: 462–475.
- Pesendorfer M.B., Dickerson S. & Dragoo J.W. 2018: Observation of tool use in striped skunks: how community science and social media help document rare natural phenomena. *Ecosphere* 9: e02484.
- Pourlis A.F. 2011: Developmental malformations of avian species. Manifestations of unknown or genetic etiology – a review. *Asian J. Anim. Vet. Adv.* 6: 401–415.
- Robb E.A., Antin P.B. & Delany M.E. 2013: Defining the sequence elements and candidate genes for the coloboma mutation. *PLOS ONE* 8: e60267.
- Schmidt R.E. 1971: Colobomas in non-human primates. *Folia Primatol.* 14: 256–268.
- Schmidt R.E. & Toft J.D. 1981: Ophthalmic lesions in animals from a zoologic collection. *J. Wildl. Dis.* 17: 267–275.
- Seruca C., Molina-López R., Peña T. & Leiva M. 2012: Ocular consequences of blunt trauma in two species of nocturnal raptors (*Athene noctua* and *Otus scops*). *Vet. Ophthalmol.* 15: 236–244.
- Shirk J.L., Ballard H.L., Wilderman C.C. et al. 2012: Public participation in scientific research: a framework for deliberate design. *Ecol. Soc.* 17: 29.
- Stoll C., Alembik Y., Dott B. & Roth M.P. 1997: Congenital eye malformations in 212,479 consecutive births. *Ann. Genet.* 40: 122–128.
- Sullivan B.L., Aycrigg J.L., Barry J.H. et al. 2014: The eBird enterprise: an integrated approach to development and application of citizen science. *Biol. Conserv.* 169: 31–40.
- Šálek M., Bažant M., Klvaňa P. et al. 2023: Historical changes in mortality patterns of diurnal and nocturnal raptors in the Czech Republic, Central Europe: 1913–2017. *Biol. Conserv.* 282: 110073.
- Šálek M., Chrenková M., Dobrý M. et al. 2016: Scale-dependent habitat associations of a rapidly declining farmland predator, the little owl *Athene noctua*, in contrasting agricultural landscapes. *Agric. Ecosyst. Environ.* 224: 56–66.
- Šálek M., Chrenková M. & Kipson M. 2013: High population density of little owl (*Athene noctua*) in Hortobágy National Park, Hungary, Central Europe. *Pol. J. Ecol.* 61: 165–169.
- Šálek M., Monoki Á., Madhavan M. et al. 2025: In owl's paradise: little owl population densities in traditional human settlements represent one of the highest densities reported among owls. *J. Raptor Res.* 59: 1–11.
- Šálek M., Poprach K., Opluštil L. et al. 2019: Assessment of relative mortality rates for two

- rapidly declining farmland owls in the Czech Republic (Central Europe). *Eur. J. Wildl. Res.* 65: 1–11.
- Šálek M. & Schropfer L. 2008: Population decline of the little owl (*Athene noctua*) in the Czech Republic. *Pol. J. Ecol.* 56: 527–534.
- van Nieuwenhuyse D., Génot J.-C. & Johnson D.H. 2008: The little owl: conservation, ecology, and behavior of *Athene noctua*. Cambridge University Press, Cambridge, UK.
- Verma A.S. & FitzPatrick D.R. 2007: Anophthalmia and microphthalmia. *Orphanet J. Rare Dis.* 2: 1–8.
- Wilcox F.H. 1958: Studies on the inheritance of coloboma of the iris in the domestic fowl. *J. Hered.* 49: 107–110.

Supplementary online material

Table S1. List of sampling localities, sampling periods, number of sampled species and individuals, and data collectors.

Table S2. The number of positive coloboma cases in sampled birds. We also mention the number of negative cases, birds with distinct eye flecks, the total number of sampled individuals, the prevalence of coloboma, and its 95% confidence intervals in sampled bird species.

(<https://www.ivb.cz/wp-content/uploads/JVB-vol.-74-2025-Mikula-P.-et-al.-Table-S1-S2-003.xlsx>)